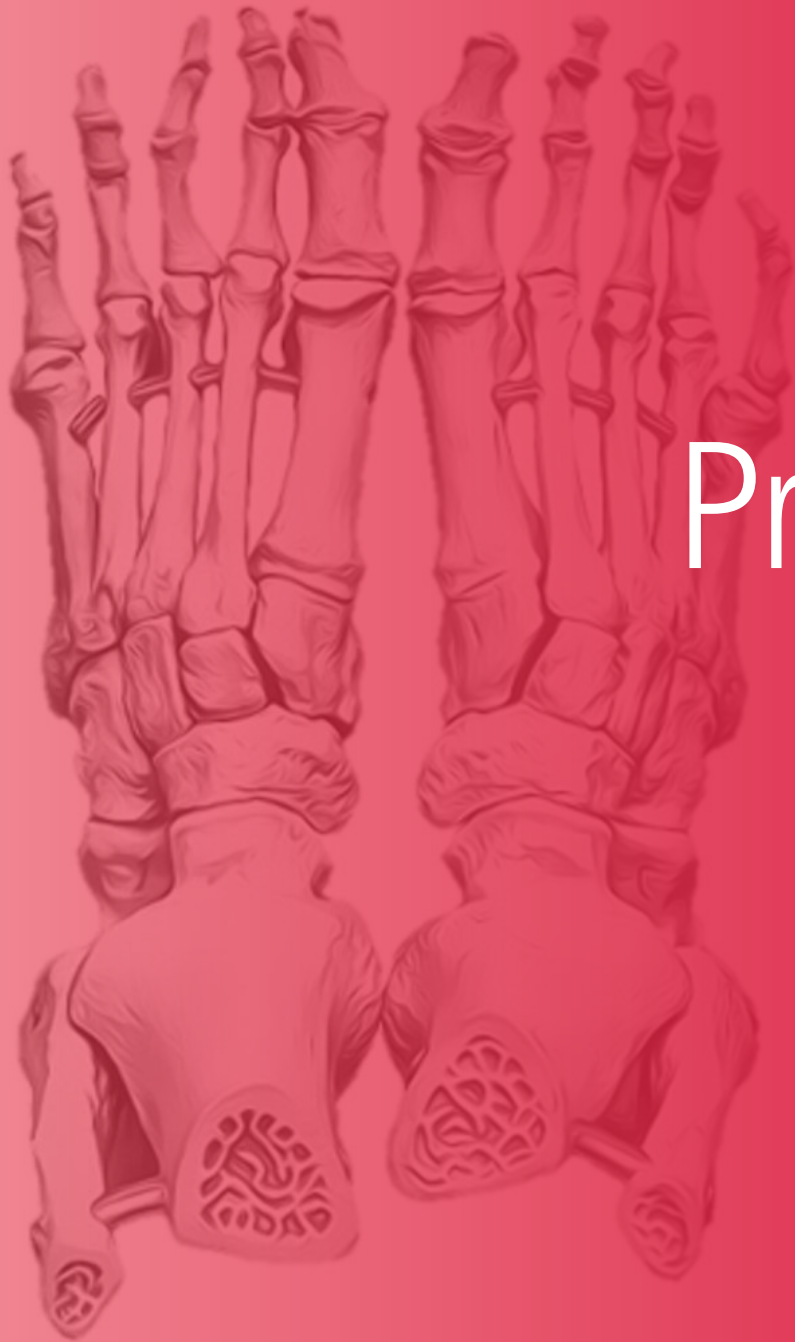



PrePodiatryStudy Case Studies



PrePodiatryStudy

Ankle Fracture

Case

HPI:

A 29-year-old male presents to ED by ambulance for Motor Vehicle Accident (MCA). Patient states her right foot really hurts. ED physician has already stabilized patient and paged you to come assess the patient. She denies any neck, chest, hip, or upper extremity injury.

What do you want to know next?

Past Medical History

PMH:

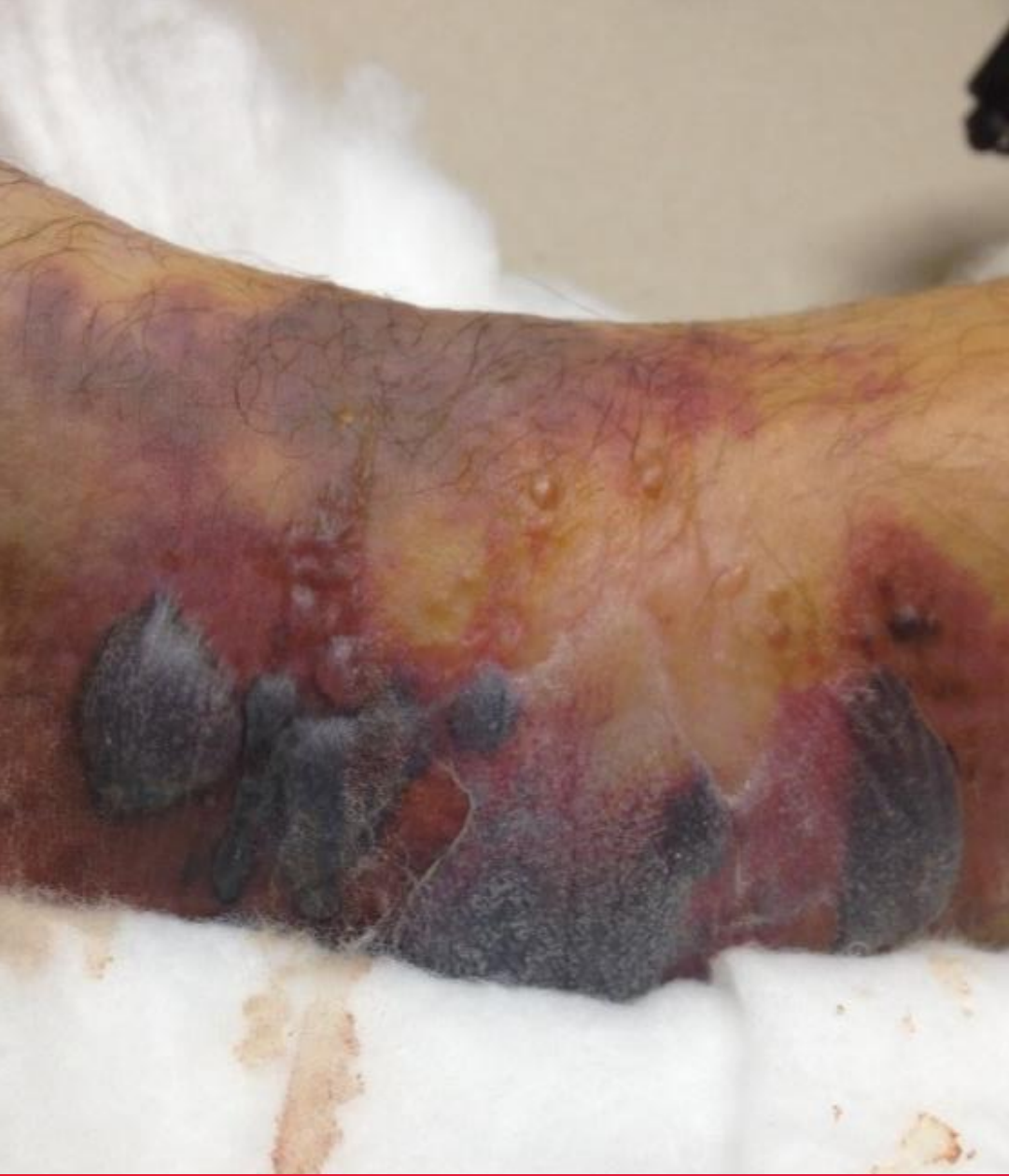- Illnesses: Healthy
- Meds: No Medications
- Allergies: Penicillin
- FH: Non-contributory
- SH: 1 PPD tobacco x 20 years, 2 drinks ETOH a day, (+) marijuana

What do you want to know next?

Physical Exam

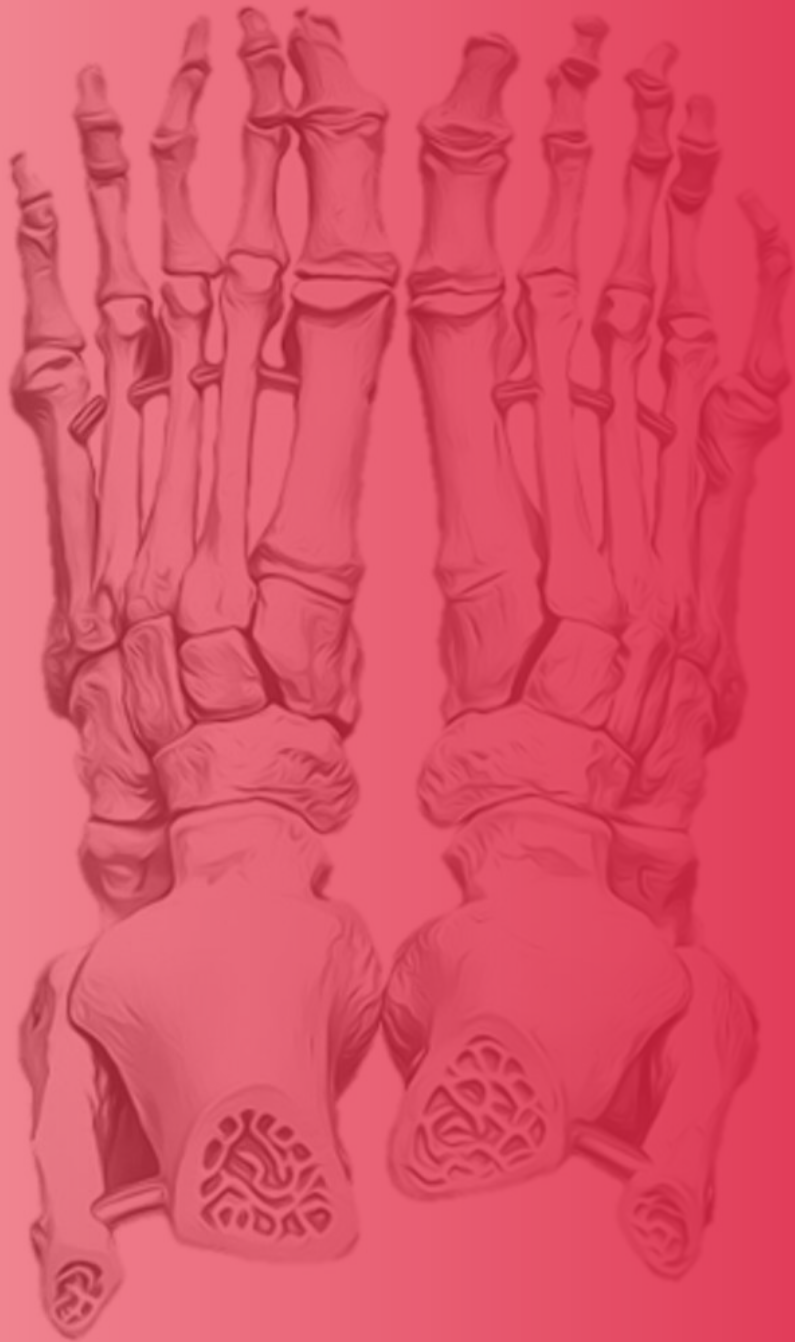- Vascular
 - DP/PT palpable pulses
 - +1 non pitting edema of left ankle
- Dermatologic
 - Blood blisters lateral ankle
 - (-) Openings, lacerations
 - (+) Ecchymosis to left ankle
- Neurologic
 - (+) sensation with 10g SWMF
- Musculoskeletal
 - Pain on ankle range of motion
 - Able to move toes
 - 5/5 Strength right, Guarded left
 - No ankle dislocation noted

What is the difference between Clear & Bloody trauma blisters?

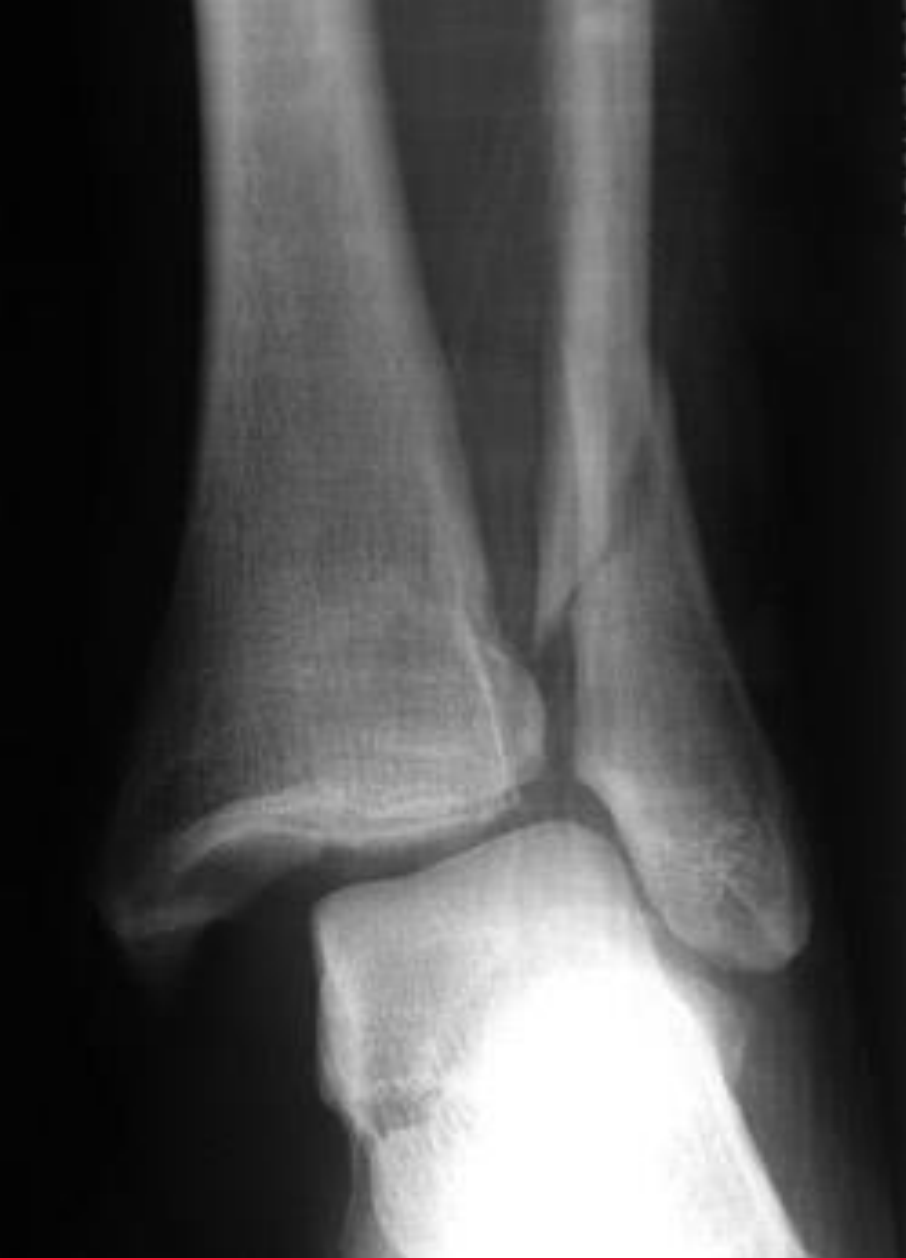

Clinical Image

Read the image.



Read Me This Xray



Imaging

Read the image.

Imaging

- Anterior-Posterior View (AP View)
 - Classify the injury using two different systems?
 - Denis-Weber Classification
 - Lauge-Hansen Classification
 - Any further diagnostic imaging you would like to get?
 - How would you reduce this injury?

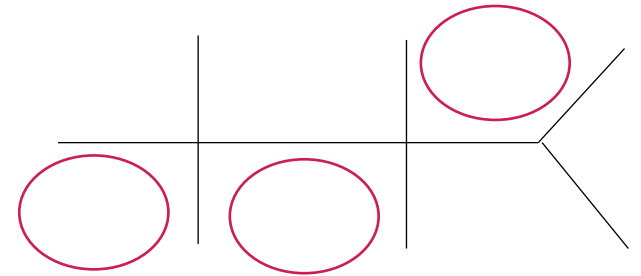
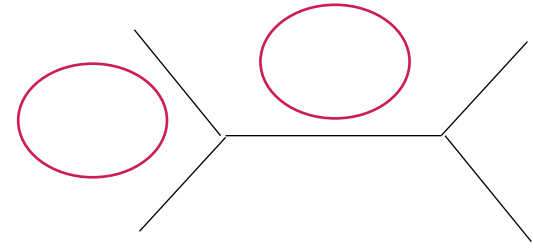
What would you order next?



Labs?

Labs

- CBC (complete blood count)
- BMP (basic metabolic panel)
- PT/INR, PTT. **What is INR?**
- Type & screen
- Nicotine & Drug screen



What are the normal values of the circled labs?

An anatomical illustration of two hands, palms facing each other, wearing surgical gloves. The gloves are light-colored with a textured surface. The hands are positioned on the left side of the slide, with the fingers pointing upwards. The background is a solid dark red color.

After waiting 2 weeks for blistering to decrease...

What's your surgical
plan, Doctor?

Plan

- Incision placement?
- What kind of plate do you use?
- Screw size? 2.7, 3.5, 4.0, 6.0mm?
- Do you need a syndesmotic screw?
- Cortical or cancellous?
- Partially threaded or Fully threaded?
- What is an interfrag screw?

Plan

- Pain Meds?
- Post-Op protocol?
- Return to clinic in how many days?
- When to take sutures out? 7 days? 14 days? 20 days?
- When to take X-rays?
- When do you start weightbearing? Why?
- When to return to regular running shoe?



Rapid Fire Questions

Rapid Fire Questions

- What ligaments comprise the syndesmosis?
- What nerve must you avoid when making incision at the fibula?
- What type of joint is the ankle joint classified?
- When do you fix posterior malleolar fractures?
- What angle does the magic angle effect occur?

Rapid Fire Questions

- Describe Ramsey and Hamilton's study?
- How can you check if the syndesmosis can be ruptured?
- Where will you place your syndesmosis screw?
- Will you keep the foot in neutral, DF, or PF when you place your syndesmotic screw?
- Will you take out the syndesmotic screw? Why or why not? If so, when?



Answers

Case

HPI:

A 29-year-old male presents to ED by ambulance for Motor Vehicle Accident (MVA). Patient states her right foot really hurts. ED physician has already stabilized patient and paged you to come assess the patient. She denies any neck, chest, hip, or upper extremity injury.

What do you want to know next?

- Open wounds? Skin Tinting? Tetanus? Last meal?
- Tingling, numbness, burning, shooting pain? Neurovascular assessment?
- Any headaches, changes to vision, SOB?



Imaging

Read the image.

“This is a radiograph of the left foot, AP View, showing a spiral oblique fracture of the fibula at the trans-syndesmotic level with no comminution, signs of fibular shortening and displacement. There is disrupted Shenton’s lines, and dime sign. Furthermore, there is increase medial gutter widening with the talus laterally displaced. No signs of medial malleolar fracture. My impression is...”

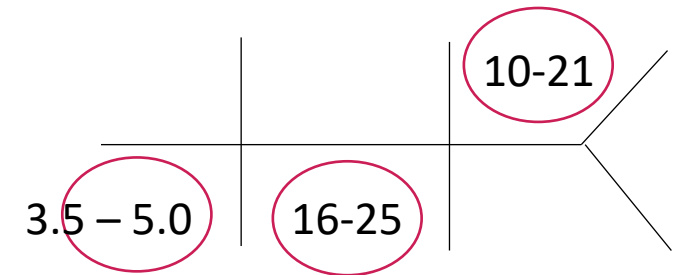
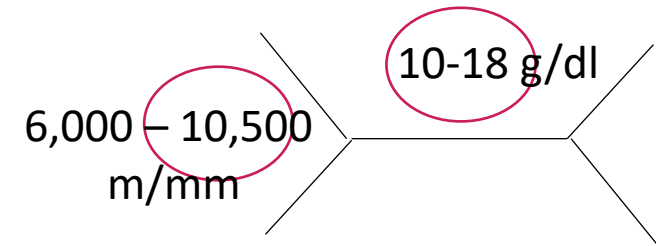
Imaging

- Anterior-Posterior View (AP View)
 - Classify the injury using two different systems?
 - Denis-Weber Classification – **Weber B**
 - Lauge-Hansen Classification – **Lauge Hansen SER 4, due to disruption of deltoid ligament**
 - Any further diagnostic imaging you would like to get? **CT, Xray of spine, or foot**
 - How would you reduce this injury?

What would you order next?

Labs

- CBC (complete blood count)
- BMP (basic metabolic panel)
- PT/INR, PTT. **What is INR?**
International normalized ratio
- Type & screen
- Nicotine & Drug screen



What are the normal values of the circled labs?

Rapid Fire Questions

- What ligaments comprise the syndesmosis?
 - AITFL, PITFL, interosseous ligament
- What nerve must you avoid when making incision at the fibula?
 - Sural Nerve
- What type of joint is the ankle joint classified?
 - A Hinge type synovial joint
- When do you fix posterior malleolus fractures?
 - Per McDaniel Article , when >25% or greater than 2-5cm translated
- What angle does the magic angle effect occur?
 - 54.74 on MRI

Rapid Fire Questions

- Describe Ramsey and Hamilton's study?
 - 1cm lateral shift of the talus causes 42% decrease in surface area of Talotibial joint
- How can you check if the syndesmosis can be ruptured?
 - Squeeze test, external rotate, or gravity foot test. In surgery, do a Hook test.
- Where will you place your syndesmosis screw?
 - 2-4 cm proximal to AJ or 1cm to syndesmosis
- Will you keep the foot in neutral, DF, or PF when you place your syndesmotic screw?
 - Dorsiflex the foot b/c talar dome is wider anterior
- Will you take out the syndesmotic screw? Why or why not? If so, when?
 - Before Weight Bearing, since it may lead to breakage of the screw



PrePodiatryStudy
Thank You